

An Enhance Approach for Multiple Region Tumor Detection in MRI Brain Image and its Comparison with Existing Methods

Ms. Rutuja Umalkar

ME Student

Department of Computer Science & Engineering
Nagpur Institute of Technology, Nagpur, India

Abstract— A hybrid technique is being proposed for classification of brain tissues in magnetic resonance photos (MRI) based totally on the method adopted. A wavelet based totally texture feature set is derived. The most useful texture capabilities are extracted from regular as well as tumor regions through the usage of spatial gray level dependence technique. The proposed technique resolves the massive trouble of category strategies. These most efficient functions are then used to categories the brain tissues into benign, every day, or malignant tumor. The overall performance of the set of rules is evaluated based totally on a sequence of brain tumor photographs.

Key words: Tumor Detection, MRI Brain Image

I. INTRODUCTION

Brain tumor is one of the prime causes behind the increase in mortality among people. A tumor is an abnormal growth caused by cells reproducing themselves in an uncontrolled manner. Brain tumor is one of the leading causes of cancer - related deaths. Depending on the direction in which the tumor is spreading, the brain tumor is classified into various types and the course of action for its treatment is chosen. There are two main types of tumors: malignant or cancerous tumors and benign tumors. Cancerous tumors can be divided into primary tumors that start within the brain, and secondary tumors that have spread from somewhere else, known as brain metastasis tumors. The effects of a brain tumor are dependent on the size and location of the tumor and how much it has spread.

Modern imaging techniques, such as MRI and CT scans, have made it possible to accurately judge the size and location of a tumor, making surgery possible where the growth is accessible, and allowing them to estimate how treatable it is.

Brain tumor segmentation for MR images is a difficult and challenging task due to variation in type, size, location and shape of tumors. Real time diagnosis of tumors by using more reliable algorithms has been the main focus of the latest developments in medical imaging and detection of brain tumor in MR images and CT scan images has been an active research area. The separation of the cells and their nuclei from the rest of the image content is one of the main problems faced by most of the medical imagery diagnosis systems. The process of separation i.e. segmentation, is paid at most importance in the construction of a robust and effective diagnosis system. Images Segmentation is performed on the input images

Primary brain tumors result from a genetic mutation in certain nerve cells in the brain (neurons) that causes them to grow too quickly. Secondary brain tumors result only after cancer has grown in another part of the body and then spread to the brain.

Imaging technology in Medicine made the doctors to see the interior portions of the body for easy diagnosis. CT scanner, Ultrasound and Magnetic Resonance Imaging took over x-ray imaging by making the doctors to look at the body's elusive third dimension. Image processing techniques developed for analyzing remote sensing data may be modified to analyze the outputs of medical imaging systems to get best advantage to analyze symptoms of the patients with ease. There are various advantages of using digital images techniques like data is not changed when it is reproduced again and again and retains originality, enhancement of images makes work easier for physicians to interpret and quick comparison of images.

A brain tumor is an abnormal growth of cells within the brain, which can be cancerous or non-cancerous (benign). It is generally caused by abnormal and uncontrolled cell division, normally either in the brain itself (Neurons, Glial Cells (Astrocytes, Oligodendrocytes, Ependymal Cells), lymphatic blood vessels), in the cranial nerves (myelin-producing Schwann cells), in the brain envelopes (meninges), skull, pituitary and pineal gland, or spread from cancers primarily located in other organs (metastatic tumors).

Brain tumors are of two types: primary and secondary. Primary brain tumors include any tumor that starts in the brain. Primary brain tumors can start from brain cells, the membranes around the brain (meninges), nerves, or glands.

Primary brain tumors are classified as:

- 1) Benign.
- 2) Malignant.

Benign tumors can be removed, and they seldom grow back. Benign brain tumors usually have an obvious border or edge. They don't spread to other parts of the body. However, benign tumors can press on sensitive areas of the brain and cause serious health problems. Malignant brain tumors are generally more serious and often are a threat to life. They are likely to grow rapidly and crowd or invade the nearby healthy brain tissue. Cancer cells may break away from malignant brain tumors and spread to other parts of the brain or to the spinal cord. They rarely spread to other parts of the body

Magnetic resonance imaging (MRI) provides detailed information about brain tumor anatomy and acts as an essential preprocessing step for tumor detection. Magnetic resonance imaging (MRI), or nuclear magnetic resonance imaging (NMRI), is primarily a medical imaging technique used in radiology to visualize detailed internal structure and limited function of the body. MRI provides much greater contrast between the different soft tissues of the body than computed tomography (CT) does.

A. Common Testing

Brief description of common tests follows:

- 1) Glasgow Coma Scale. Often times administered by paramedics during ambulance transport from the scene of an accident, the Glasgow Coma Scale rates
 - A patient's ability to open his/her eyes;
 - motor responses to verbal/painful stimulus; and
 - Verbal responses.

Modern definitions of mild traumatic brain tumor allow for a Glasgow Coma Scale score of Between 13 to 15. Under the Scale itself, a person generally thought to be alert and oriented would be rated 15, while an unresponsive comatose individual would rate as low as 3.

- 2) b) Sophisticated Imaging. Various sophisticated imaging tests may have been performed diagnostically in the hospital or radiology setting.

These include:

- Skull x-rays;
- CT Scans(Computed Tomography);
- MRI Scans(Magnetic Resonance Image); and
- EEG (Electro-encephalography) studies.

Generally speaking, this imaging is extremely helpful in cases involving skull fractures as well as hematomas, or hemorrhages which may occur at a variety of locations in the brain. These imaging tests may reveal no positive findings, however, in cases involving "mild traumatic brain tumor. Often times, "mild" to "moderate" traumatic brain tumor involves diffuse axonal injury caused by shearing forces. Indeed, axonal degeneration is only seen in the traumatized brain. Yet, its direct visualization is not presently technologically feasible except when a large number of clustered neurons are interrupted. Following death, however, neuropathological investigation clearly evidences diffuse axonal hearing.

II. LITERATURE REVIEW

Medical imaging has become the key to access inside human brain/head for the purpose of diagnosis and treatment planning. In order to understand the effectiveness of planned treatment following the diagnosis, treated brain/head part may have to be monitored several times during a period of time. Information gained from successive imaging of brain/head part provides guidance to next step of treatment. Comparison of images or datasets taken at different times requires registration of these images or datasets since the same conditions may not be provided at all times.

Accurate segmentation of the brain/head part under treatment is needed while comparing medical images to achieve quantitative and qualitative measurements. This segmentation task enables two dimensional and three-dimensional visualizations of the region which also aid in directing the planning strategy. In past, several segmentation algorithms are investigated and a hybrid segmentation algorithm is developed in order to segment bone tissue out of head CT slices for orthodontic treatment planning. Using the developed segmentation algorithm, three dimensional visualizations of segmented bone tissue out of head CT slices of two patients are obtained. Visualizations are obtained using the MATLAB Computer software's visualization library. Besides these, methods are developed for automatic registration of two dimensional and three-dimensional CT images taken at different time periods. These methods are

applied to real and synthetic data. Algorithms and methods are implemented in MATLAB computer program. Medical Imaging gained an increased importance over the past thirty years after the invention of the computerized tomography and various researches have been carried out since then. The discovery of computerized tomography scan revolutionized medical diagnosis, allowing doctors to see exactly what is going on inside the brain/head. Combined with powerful, robust and fast segmentation, registration and visualization algorithms, it is now possible to carry out surgical planning even during the operation.

In [2], propose a hidden Andrei Markov random field- Expectation Maximization (HMRP-EM) and threshold techniques for detection of brain tumor from MRI scan images.

An image mining technique for brain tumor classification exploitation cropped association rule with MARI formula using association rule mining technique is proposed in [4]. It combines the low-level options extracted from pictures and high level data from specialists.

In [5] planned early prediction of brain cancer supported texture options and neuro classification logic. 9 distinct options in conjunction with minimum distance area unit used for brain tumor detection in given MRI image. Extracted region is recognized exploitation neuro fuzzy approach.

In [6] [12] designed of uncovering strategies to eliminate the non-brain tissue in resonance (MR) brain pictures. The pre-segmentation step is employed to seek out the optimum place to begin for the deformation and relies on thresholds and morphological operators. The deformable model relies on a simplex mesh and its deformation is controlled by the image native grey levels and also the data obtained on the grey level modeling of the pre-segmentation. Then the author tested Simplex Mesh and bar graph Analysis of uncovering (SMHASS) technique on the subsequent international databases unremarkably utilized in scientific articles: Brain Web, net Brain Segmentation Repository (IBSR), and Segmentation Validation Engine (SVE). During this paper a comparison was performed against 3 of the most effective uncovering strategies antecedently published: Brain Extraction Tool (BET), Brain Surface Extractor (BSE), and Hybrid Watershed formula (HWA).

In [7] the most technique used was segmentation that is completed employing technique supported threshold segmentation, watershed segmentation and morphological operators. In [7][13] the planned segmentation technique was experimented with MRI scanned pictures of human brains: therefore locating tumor within the pictures. In [13] conjointly mentioned future work is to increase their planned technique for color based mostly segmentation of 3D pictures. For this purpose would like a classification technique to prepare 3 dimensional objects into separate feature categories, whose characteristics will facilitate in identification of brain diseases.

In [8] evaluated nucleon man spectroscopy for brain tumor categorization. Brain tumors area unit classified into low-high grade interstitial tissue neoplasm, meningiomas and metastasis. Brain tumors area unit classified on the premise of Cho/NAA, Cho/Cr and Cho/MI substance ratios. In [8] applied changed segmentation techniques on MRI scan

pictures to observe brain tumor. Changed Probabilistic Neural Network supported Learning Vector division. With image and knowledge analysis to classify brain tumor exploitation MRI scans.

In [9], the watershed and thresholding formula is evaluated for the detection and segmentation of brain tumor. Edge base segmentation and color base segmentation, Cohesion self-merging based mostly partition K-mean algorithm applied to extract the boundary and dimensions of the tumor. Morphological operation is applied to MRI pictures of brain.

III. PROPOSED APPROACH

This proposed work is to detect and segment the tumor region in the brain MRI using Contextual Clustering algorithm and to show that its accuracy in the tumor segmentation is higher when compared to all other already used conventional methods. The processes in this proposed work are:

- 1) The MRI of brain is taken as the input image.
- 2) Then Image preprocessing is carried out in that MRI of brain.
- 3) The Contextual Clustering algorithm is applied to that pre-processed image to segment the tumor region.

This work involves

- 1) Image Pre-Processing
- 2) Tumor Segmentation

1) Image Pre-Processing:

- The visual appearance of input MRI images is enhanced.
- And the manipulation of input datasets is improved. This Image pre-processing does sub function.
- Image resizing and gray scale conversion.

a) Image Resizing and Gray Scale Conversion First resizing of the input MR image is carried out where the image gets enlarged. Then the gray scale conversion takes places.

Tumor Segmentation After the preprocessing process the tumor region segmentation takes place using the Contextual Clustering algorithm.

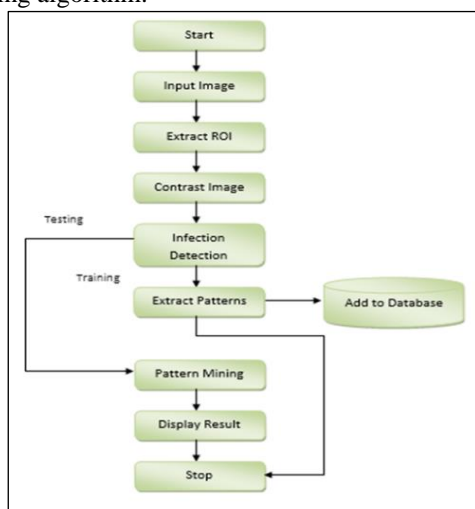


Fig. 5.1:

IV. METHODOLOGY

The proposed method to detect the tumor here is an efficient method as compared to other conventional methods. The code

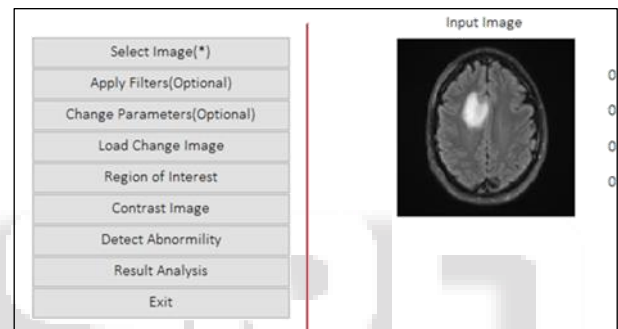
is developed using Matlab. The MRI image is enhanced and processed to get clear digital image as a input. The Region of interest image is then selected. Applying proposed method, the infected region is detected. The infection level, infection percentage, and tumor type are evaluated using the current method. Once the output image is ready we can analyze the tumor level, its type and the degree of infection.

We have compared proposed method with existing conventional methods like PSO, K-means, Fuzzy C-means. Same tumor infection output is carried out using all these above existing methods. But as we are comparing the outcomes of our proposed method with all other conventional methods which are used in medical science nowadays, We find the proposed method is more efficient and precise as a result.

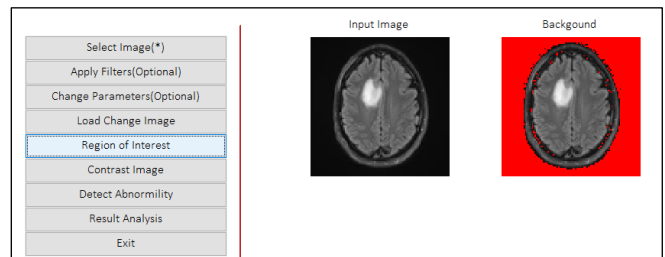
Following are the factors/parameters involved in proposed method.

A. Input Image

An Input image is MRI Scan Image from an Authenticate source device.



ROI (Region of interest): region of interest is a portion of an image that you want to filter or perform some other operations on. This region of interest shows precise section where we have to do analysis of tumor. Boundaries of tumor may be defined on an image for the purpose of measuring its size.



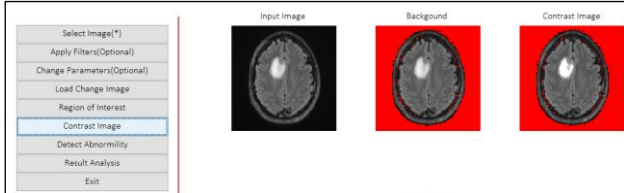
B. Algorithm (Region of Interest)

- 1) Start
- 2) Input Image I
- 3) Set threshold
- 4) For i=1:Width(I)
- For j=1: Height (I)
- Read Pixel p (i, j)
- Extract R, G, B from p (i, j)
- If R <=threshold && G<=threshold && B<=threshold
- I (i, j, 1) =255;
- I (i, j, 2) =0;
- I (i, j, 3) =0;
- End
- End

- End
 5) Save Image I
 6) Stop

C. Enhance Image

Enhancing is the process of adjusting digital images so that results are more accurate for further image analysis. Enhancing technique may be wavelet base enhance/histogram equalization base method.

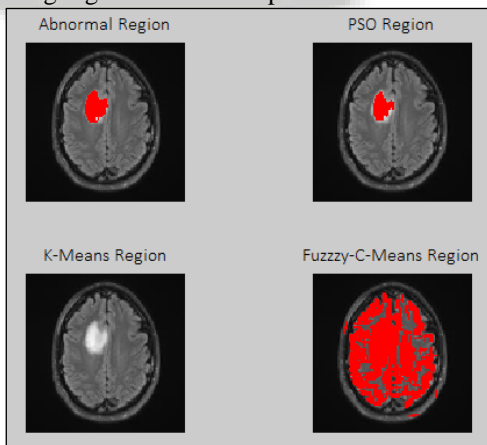


D. Algorithm (Contrast Image)

- 1) Start
- 2) Input Image I
- 3) Set threshold
- 4) For i=1:Width(I)
 For j=1: Height (I)
 Read pix = I (i, j)
 If (pix>=200 && pix<=255)
 I (i, j, 1)=255;
 I (i, j, 2)=255;
 I (i, j, 3)=255;
 End
 End
 End
- 5) Save Image I
- 6) Stop

E. Infection detection

The infected area of tumor is determined. Only infected region is highlighted with exact precision.




F. Algorithm (Detect Abnormality)

- 1) Start
- 2) Input Contrast Image I
- 3) Set threshold, Count=0;
- 4) For i=1:Width(I)
 For j=1: Height (I)
 Read
 PixR= I (i, j, 1)
 PixG= I (i, j, 2)

- PixB= I (i, j, 3)
- If (PixR>=threshold && PixG>=threshold && PixB>=threshold)
- Count = count + 1;
- If count ==Count Frequency
- Set Horizontal Pixel to 255
- Count =0;
- End
- Else
- Set Pixel to 0
- Count =0;
- End
- End
- End
- 5) Save Image I
- 6) Stop

G. Extract patterns

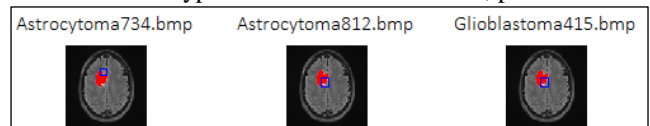
The patterns are extracted and that can be classified under different tumor types. The medical knowledgeable individuals can classify it accordance with their types and severity. These defined patterns are then added to the database for future references.



H. Algorithm (Image Registration)

- 1) Input Original Image I
- 2) Input Abnormality Detected Image IA
- 3) Set Threshold
- 4) For i=1:Width(I)
 For j=1: Height (I)
 Read
 PixR=IA (I, j, 1);
 PixG=IA (I, j, 2);
 PixB=IA (I, j, 3);
 If (pixR>= Threshold && pixG>= Threshold && pixB>= Threshold)
- Set
 I (I, j, 1)=255;
 I (I, j, 2)=0;
 I (I, j, 3)=0;
- End
- 5) Save Image I
- 6) Stop

Trace Abnormal Patterns: The resulted pattern of the next infected tumor image can easily analyzed and determine as it is of which type and class like metastatic, padaeatric etc.



I. Algorithm (Trace Abnormal Patterns)

- 1) Start
- 2) Load Registered Image R
- 3) Load Pattern Database Images PD

- 4) For i=1:Length(PD)
 - Read PD (i)
 - Locate PD (I) in R
 - If Found ==true
 - Draw Rectangle on R
 - End
- 5) Stop

J. Display result

The result with all analysis is displayed with all parameters and its comparison with other conventional methods.

K. Clustering Method

Clustering will be done with C- Fuzzy Means / PSO/ K means and with other methods for comparative analysis.

V. EXPERIMENTAL RESULT

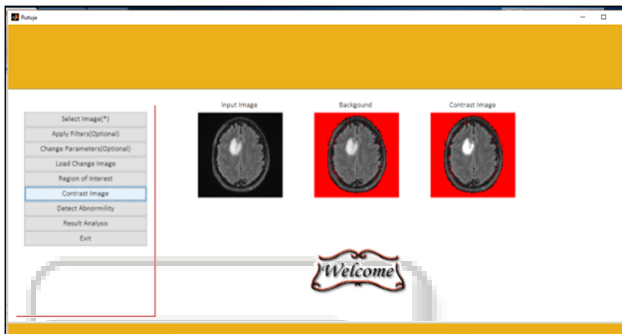


Fig. 1: GUI

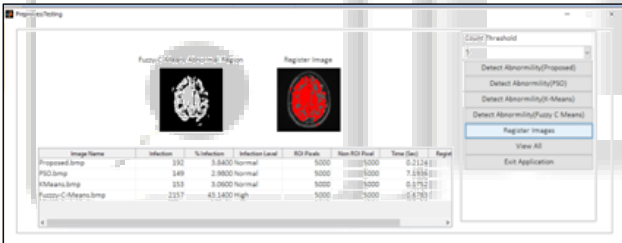


Fig. 2: GUI Representing infected area location and its result analysis

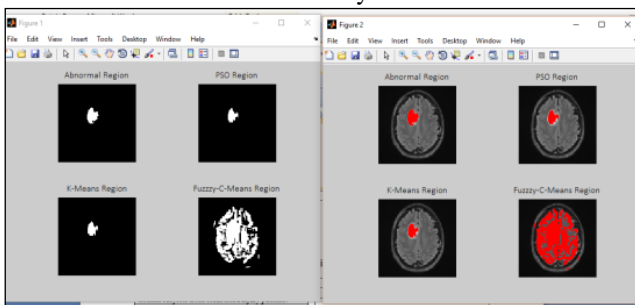


Fig. 3: Infection Located Vs Registered Images

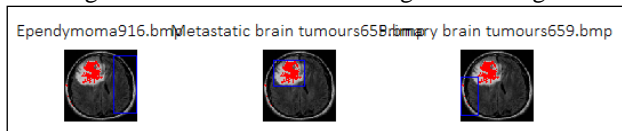


Fig. 4: Pattern Mining

VI. DISCUSSION & CONCLUSION

In this work a unique technique is developed with normal and benign or malignant tumor classes. The medical decision-making system is designed using edge detection & matrix

correlation. The proposed approach gives very promising results in classifying the healthy and pathogen affected brain. We have compared the tumor image outcome of proposed method with all other existing conventional methods, upon which the proposed approach is proved as more efficient and accurate. The system is beneficial in assisting the physician to make the final decision. The proposed algorithm is efficient for classification of the human brain as normal or abnormal (benign and malignant Tumor) with high rate of sensitivity and accuracy. Based on performance obtained, the technique is accurate, robust, easy to operate, non-invasive and cheap which is advantageous. A major limitation of this method is that it requires fresh training for each new set of image database.

Image Name	Infection	% Infection	Infection Level	ROI Pixels	Non ROI Pixel	Time (Sec)	Registration Time (Sec)
Proposed.bmp	192	3.8400	Normal	5000	5000	0.1658	0.0735
PSO.bmp	149	2.9800	Normal	5000	5000	11.4333	0.0606
KMeans.bmp	0	0	Normal	5000	5000	0.4104	0.0558
Fuzzy-C-Means.bmp	2157	43.1400	High	5000	5000	0.9411	0.0643

REFERENCES

- [1] Head injury: Triage, assessment, investigation and early management of head injury in infants, children and adults; NICE clinical guideline 56, Developed by the National Collaborating Centre for Acute Care.
- [2] Michael D Gilchrist, Modelling and Accident Reconstruction of Head Impact Injuries. Key Engineering Materials vols 245-246(2003) pp 417-429.
- [3] Miao M Chong, Ajith Abraham, MarcinPaprzycki, Traffic Accident Analysis using decision trees and Neural networks.
- [4] Medha V. Wyawahare, Dr. Pradeep M. Patil, and Hemant K. Abhyankar, Image Registration Techniques: An overview, International Journal of Signal Processing, Image Processing and Pattern Recognition, Vol. 2, No.3, September 2009.
- [5] B.Balasubramaniam, Dr.K.Porkumaran, Registration of PET and MR Images of Human Brain using Normalized Cross Correlation Algorithm and Spatial Transformation Technique..
- [6] Matthew C Clark, Lawrence O Hall, Robert Velthuizen, Automatic Tumor Segmentation using Knowledge-based Technique, IEEE Transaction on Medical Imaging, Vol 17,no.2, April 1998.
- [7] XiaojunZang, Yongtian Wang, Jian Yang, Yue Liu , A Novel Method of CT Brain Images Segmentation, 2010 International Conference of Medical Image Analysis and Clinical Application.
- [8] Mrs. Mamata S Kalas, An Artificial Neural Network for Detection of Biological Early Brain Cancer, 2010 International Journal of Computer Application, volume 1-no.6.
- [9] Rizhe Liu, Chew Lim Tam, TzeYun Leong, Hemorrhage Slices Detection in Brain CT Images, @2008 IEEE.
- [10] Sohini Roy Chowdhari , AG-MIC azure based generalized floe for medical image classification, Sept 2,2016 IEEE.
- [11] M.A. Nishara Banu,B Gomathi, Disease predicating system using data mining techniques, International journal of technical research and application Vol 1 Nov-Dec 2013.

- [12] Eka Miranda , mediana Aryuni, A survey of medical image classification and techniques, National journal 2014 IEEE.
- [13] Liang Lin, Wei yang. Inference with collaborative model for interactive tumor segmentation in medical image sequence. @2015 IEEE
- [14] Mehdi Teimouri, Fershad Farzadfar. Detecting disease in medical prescription using data mining tools and techniques Journal of pharmaceuticals research 2016.
- [15] Elena S Yelmanova, Yuriy M Romanyshyn. No reference contrasts matrix for medical image @ 2017 IEEE, 37th international conference on Electronics and Nano technology.

