An Analysis of Ewing's Sarcoma Detection using Image Processing Techniques

Ms.P.Geetha[1] Dr.V.Selvi[2]
[1]M.Phil Research Scholar [2]Assistant Professor
[1,2]Department of Computer Science
[1]Thanthai Hans Roever College, Perambalur-621212, India [2]Mother Teresa Women's University, Kodaikanal, India

Abstract— A Ewing's sarcomas is a kind of cancer disease which develops from soft tissues like bone, fat, muscle, nerves, fibrous tissues, blood vessels and deep skin tissues. This paper presents the overall information about the Ewing's Sarcoma and overview of image processing techniques. Ewing's Sarcoma is a terrific form of cancer which affects the adjoining body areas such as bones and other supporting soft tissue of the body. It is a very rare cancer. About 1% among adult and 15% among the children is affected in this Ewing's sarcoma. For detection mainly biopsy, CT scan or MRI is done and to pursue the treatment surgery, chemotherapy, radiation is given which may increase the survival rate of the patients. The image processing techniques are applied broadly in medical images for refining prior detection and treatment stages in Ewing's Sarcoma cancer. This paper presents an analysis of ewing's sarcoma and literature survey on detection of ewing's sarcoma by previous researchers.

Key words: Computer Aided Detection and Classification, Ewing's Sarcoma, image processing, Stages of Ewing Tumors, Types of Ewing Tumors

I. INTRODUCTION

Ewing sarcoma (ES) is a rare tumor that most often occurs in adolescents and young adults. Lifestyle-related risk factors such as body weight, physical activity, diet, and tobacco use play a major role in many adult cancers. But these factors usually take many years to influence cancer risk, and they are not thought to play much of a role in childhood cancers, including Ewing tumors Studies of children with Ewing tumors have not found links to radiation, chemicals, or any other environmental exposures. Certain childhood cancers tend to run in some families. But genetic changes passed along within families are not an important risk factor for Ewing tumors [2]. Although the gene changes that cause most Ewing tumors.

Classification of Ewing tumors is a difficult task in medical images. In order to overcome such scenario an automated computer aided classification system is required. Image processing techniques are used to improve the performance of classification Ewing tumors in medical images. The following figure comprises the four basic steps in image processing system [1].

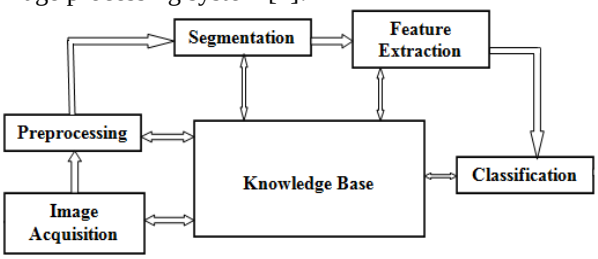

Fig. 1: Fundamentals steps in digital image processing

Digital Image Processing is largely concerned with four basic operations: image preprocessing, segmentation, feature extraction and image classification. Image preprocessing: It is the modification of image by changing the pixel brightness values to improve its visual impact. Segmentation: It refers to the process of partitioning a digital image into multiple segments. It is the process of assigning a label to every pixel in an image such that pixels with the same label share certain visual characteristics. The goal of segmentation is to simplify and change the representation of an image into something that is easier and more meaningful to analyze. Feature extraction: This technique extracts high-level features needed in order to perform classification of targets. Features are those items which uniquely describe a target, such as size, shape, composition, location etc. Image classification: The objective of image classification procedures is to automatically categorize all pixels in an image into land cover classes or themes and assigns the pixels to classes based on similar signatures [1].

II. EWING'S SARCOMA

The cause of Ewing tumors is not fully understood, but researchers are learning how certain changes in a cell's DNA can cause the cell to become cancerous. DNA is the chemical in each of our cells that makes up our genes. Genes tell our cells how to function. They are packaged in chromosomes, which are long strands of DNA in each cell. We normally have 23 pairs of chromosomes in each cell [1]. Nearly all Ewing tumor cells have changes that involve the ES gene, which is found on chromosome 22. In most cases, the change is a swapping of pieces of DNA (called a translocation) between chromosomes 22 and 11. Less often, the swap is between chromosomes 22 and 21, or rarely between 22 and another chromosome. The translocation moves a certain piece of chromosome 11 (or another chromosome) just next to the ES gene on chromosome 22, causing the ES gene to be turned on all the time. Activation of the ES gene leads to overgrowth of the cells and to the development of this cancer, but the exact way in which this happens is not yet clear [2].

Some genes control when our cells grow, divide into new cells, and die. Genes that help cells grow, divide, or stay alive are called oncogenes. Others that slow down cell division or make cells die at the right time are called tumor suppressor genes. Cancers can be caused by changes in the cell's DNA that turn on oncogenes or turn off tumor suppressor genes. Researchers have found chromosome changes that lead to Ewing tumors, but these changes are not inherited. Instead, they develop in a single cell after a child is born, for unknown reasons [3].

The most common symptom of a Ewing tumor is pain in the area of the tumor. Sometimes the tumor shows up as a lump or swelling on an arm, leg, or the trunk. Sometimes the lump feels warmer than the rest of the body, and sometimes the child has other symptoms like a fever or not feeling well. It can be diagnosed by following tests,

X-rays
Magnetic resonance imaging (MRI) scan
Sonogram
Computed tomography (CT or CAT) scan
Biopsy
Positron emission tomography (PET) scan

Table 1.

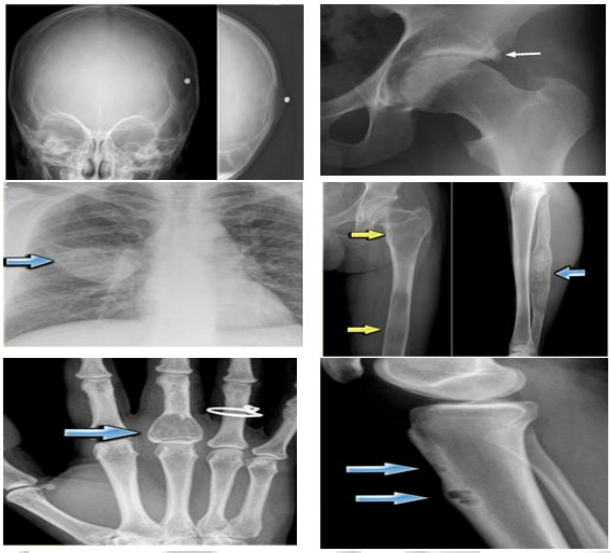

Fig. 2: Sample of Ewing Sarcoma images

A. *Types Of Ewing Tumors*

The Ewing family of tumors is a group of cancers that start in the bones or nearby soft tissues that share some common features. These tumors can develop at any age, but they are most common in the early teen years [3]. The main types of Ewing tumors are:

Type	Description
Ewing sarcoma of bone	Ewing sarcoma that starts in a bone is the most common tumor in this family. This type of tumor was first described by Dr. James Ewing in 1921, who found it was different from the more common bone tumor, osteosarcoma. Seen under a microscope, its cells looked different from osteosarcoma cells. It was also more likely to respond to radiation therapy.
Extraosseous Ewing tumor (EOE)	Extraosseous Ewing tumors start in soft tissues around bones, but they look and act very much like Ewing sarcomas in bones. They are also known as extraskeletal Ewing sarcomas.
Peripheral primitive neuroectodermal tumor (PPNET)	This rare childhood cancer also starts in bone or soft tissue and shares many features with Ewing sarcoma of bone and EOE. Peripheral PNETs that start in the chest wall are known as Askin tumors.

Table 1. Types of Ewing Tumors

Most Ewing tumors occur in the bones. Extraosseous Ewing tumors can occur almost anywhere [4]. The maximum affected parts are given in Fig 3.

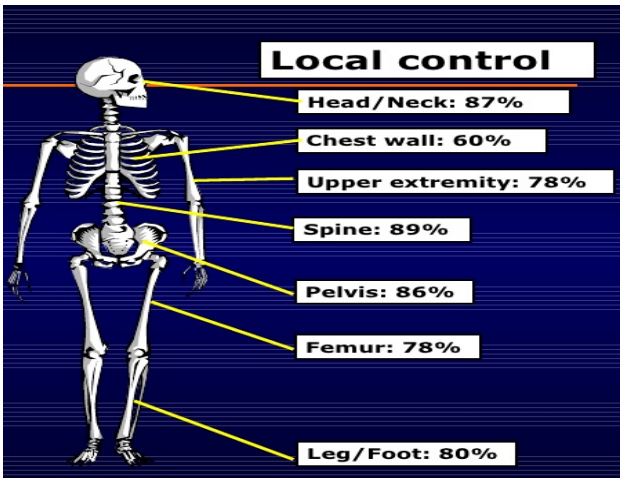

Fig. 3: Ewing Sarcoma affected site in the body

Approximately half of all people with Ewing's sarcoma of bone are under 15 years of age at diagnosis. However, it is also common in young adults. The peak ages are between 10 and 20. It is less common before the age of 5 and after the age of 30. Sometimes young adults may be treated by a "paediatric" oncologist because of the doctor's experience with treating this type of cancer.

B. *Stages Of Ewing Tumors*

Once a Ewing tumor has been diagnosed, tests are done to determine the stage of the cancer. The stage of a Ewing tumor is one of the most important factors determining a person's outlook and in choosing treatment. The stage is based on results of imaging tests and biopsies of the main tumor and other tissues [5].

- T describes the size of the main (primary) tumor and whether it appears in different areas of the bone.
- N describes the extent of spread to nearby lymph nodes. Bone tumors rarely spread to the lymph nodes.
- M indicates whether the cancer has metastasized (spread) to other organs of the body.
- G stands for the grade of the tumor, which describes how the cells from biopsy samples look. Low-grade tumor cells look more like normal cells and are less likely to grow and spread quickly, while high-grade tumor cells look more abnormal. (All Ewing tumors are considered high-grade tumors (G4)).

Primary Tumor	T1 - 8 cm or less in greatest dimension T2 - 8 cm T3 - discontinuous tumors in the primary bone site
Regional Lymph Nodes	N0 - There is no spread to regional lymph nodes N1 - The cancer has spread to nearby lymph nodes
Distant Metastases	M0 - There is no spread (metastasis) to distant organs. M1a - The cancer has spread only to the lungs. M1b - The cancer has spread to other distant sites in the body.
Grades	GX- Grade can't be assessed G1-G2-Low grade G3-G4-High grade

Table 3. Classification of Ewing Tumors

III. COMPUTER AIDED DETECTION AND CLASSIFICATION

Ewing's Sarcoma cancer cells are distinct with broad assortment of features and may be simply misapprehend by radiologists while understanding huge level of results

provided in screening programs. To aid radiologists present an accurate recognition, a computer-aided detection (CAD) and computer-aided classification (CAC) algorithms are being developed. Image processing and neural network algorithms are used to improve the performance of detecting and classifying ewing's sarcoma cancer cells in medical images. These algorithms can help doctors and radiologists for getting a more reliable and effective diagnoses and help reducing the number of false positives.

A. Literature Survey On Image Processing

Tanish Zaveri and Mukesh Zaveri attempt to detect all the information required for accurate diagnosis of a bone tumor namely, Ewing sarcoma which is simultaneously not available in individual MR images. The proposed region based image fusion method is applied on two types of MR sequence images to extract useful information which is than compared with different pixel based algorithm and the performance of these fusion schemes are evaluated using standard quality assessment parameters. From the analysis of quality assessment parameters we found that our scheme provides better result compared to pixel based fusion scheme. The resultant fused image is assessed and validated by radiologist [7].

M. Egmont-Petersen and R. J. vander Geest, states most patients with Ewing's sarcoma undergo neoadjuvant (preoperative) chemotherapy before surgery is performed. Generally, chemotherapy reduces the size of the tumor which makes the subsequent treatment more successful. MR-imaging aims at monitoring the effect of chemotherapy by identifying areas of vital remnant tumor. An MR-examination includes static T1- and T2-weighted MR-images as well as dynamic, contrast-enhanced T1-weighted MR-images. Whereas the static MR-images are used to estimate the volume of intra- and extra-osseous bone tumor, the dynamic contrast-enhanced MR-sequence indicates which parts of the tumor are highly perfused by blood. In general, malignant bone tumors are highly perfused. Moreover, these lesions are heterogenuous (sometimes multifocal) containing viable as well as nonviable (necrotic) parts. The only way to reliably distinguish viable from nonviable tumor tissue is by performing a perfusion study by dynamic contrast-enhanced MRI [8].

Abdulmuhssin and Binhssan used the image processing techniques with MRI images to detecting Bone cancer, for Image Enhancement verage & bilateral filter, Thresholding Segmentation,Morphologic al Operation classification proved its performance via performance metrics such as Sensitivity is 91.3% [9].

Jagadeeshet al [10] presented the preprocessing methods of the leukemic blast cells image in order to generate the features well characterizing different types of cells. The solved problems include: the segmentation of the bone marrow aspirate by applying the watershed transformation, selection of individual cells, and feature generation on the basis of texture, statistical and geometrical analysis of the cells.

Noorhayati Mohamed Noor et al [11] presented the enhancement capability of adaptive histogram equalization (AHE) on the soft tissue lateral neck radiograph for suspected fish bone ingestion. Due to the high resolution, the images were cropped before being processed using adaptive histogram equalization. The quality of the image was assessed and evaluated during pre and post processing by the radiologists. The result showed AHE as a promising contrast enhancement for detection of fish bone in soft tissue at the lateral neck radiographs.

Lu Zhang et al [12] described about Diffraction-enhanced imaging (DEI) and the capability of DEI to observe different types of tissues was investigated. It is a synchrotron based imaging technique, which generates high spatial resolution and contrast of both calcified and soft tissues. This technique not only provided the visualization of absorption information like conventional X-ray imaging, but also refraction and scattering properties. In this study the MIR is used to extract information from a series of DEI images.

IV. CONCLUSION

Images are imperative components in many fields of medicine, especially for the diagnosis process of bone tumors. Technology based approaches such as digital image processing help physicians to have better interpretation, faster detection and increases accuracy and objectivity of diagnosis. Looking at the experiences gained will help specialists to choose the appropriate technique for optimization of diagnosis through medical imaging. This paper presents an overview of ewing's sarcoma and literature survey on detection of ewing's tumors by previous researchers. From the literature review, it indicates that developments of new methods are required to detect ewing's tumors more efficiently.

REFERENCES

[1] Anderson ME, Randall RL, Springfield DS, Gebhart MC. Chapter 92: Sarcomas of bone. In:Niederhuber JE, Armitage JO, Doroshow JH, Kastan MB, Tepper JE, eds. Abeloff's ClinicalOncology. 5th ed. Philadelphia, Pa: Elsevier; 2014.
[2] Arnaldez FI, Helman LJ. New strategies in Ewing sarcoma: Lost in translation? Clin CancerRes. 2014;20:3050–3056.
[3] Bacci G, Longhi A, Barbieri E, et al. Second malignancy in 597 patients with Ewing sarcoma of bone treated at a single institution with adjuvant and neoadjuvant chemotherapy between 1972 and 1999. J Pediatr Hematol Oncol. 2005;27:517–520.
[4] Ewing sarcoma of bone and soft tissue and the peripheral primitive neuroectodermal tumours. In: Pizzo P, Poplack D, eds. Principles and Practice of Pediatric Oncology, Fifth Edition. Philadelphia: Lippincott, Williams and Wilkins
[5] Hawkins DS, Bolling T, Dubois S, et al. Ewing sarcoma. In: Pizzo PA, Poplack DG, eds. Principles and Practice of Pediatric Oncology. 6th ed. Philadelphia Pa: Lippincott Williams & Wilkins; 2011:987–1014.
[6] http://www.cancer.org/cancer/ewingfamilyoftumors/detailedguide/ewing-family-of-tumors-what-is-ewing-family-tumors
[7] Tanish Zaveri, Mukesh Zaveri "Region Based Image Fusion for Detection of Ewing Sarcoma" ICAPR '09 Proceedings of the 2009 Seventh International Conference on Advances in Pattern Recognition Pages

240-243 IEEE Computer Society Washington, DC, USA ©2009,ISBN: 978-0-7695-3520-3.

[8] M. Egmont-Petersen, R. J. van der Geest, H. A. Vrooman, P. C. W. Hogendoorn, H. J. van der Woude, J. P. Janssen, J. L. Bloem, J. H. C. Reiber"Segmentation of Dynamic Contrast-Enhanced MR-Images of Post Chemotherapy Ewing's Sarcoma with a Pharmacokinetic Model and a Neural Network" Springer.

[9] Abdulmuhssin Binhssan "Enchondroma tumor Detection International Journal of Advanced Research in Computer and Communication Engineering,Vol. 4, Issue 6, June 2015.ISSN (Online) 2278-1021

[10] S.JagadeeshDr.E.NagabhooshanamDr.S.Venkatachalam , "Image processing based approach to cancer cell prediction in blood samples"International Journal of Technology and Engineering Sciences, vol. 1, pp.1- 4.

[11] Noorhayati Mohamed Noor, Noor Elaiza Abdul Khalid. "Fish Bone Impaction Using Adaptive Histogram Equalization (AHE)" Proceedings of the Second International Conference on Computer Research and Development 2010, IEEE Computer society Washington, pp.163-167.

[12] Lu Zhang, Dongyue Li, ShuqianLuo , "Information extraction of bone fracture images based on diffraction enhanced imaging" International Conference of Medical Image Analysis and Clinical Application (MIACA) 10-17 June 2010, pp. 106 -108.

